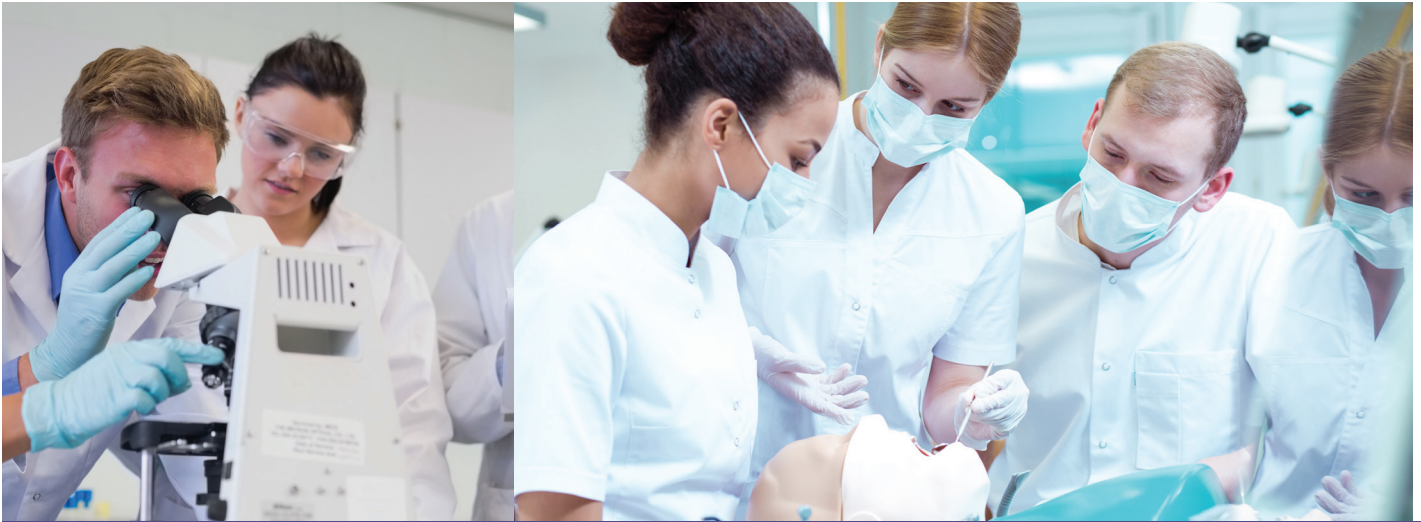



Advanced Dental Admission Test (ADAT) Practice Test



Important notice and disclaimer concerning these practice items

The following items are offered to help candidates understand the types of questions that will be asked on the Advanced Dental Admission Test (ADAT). It should be noted that practice test questions are not subjected to the same intense scrutiny, and do not undergo the same level of review as items appearing on the actual examination. When developing examination content, the best questions are always reserved for placement on the actual examination itself (as opposed to placement on distributed lists of practice questions). The ADA recommends that you use textbooks and lecture notes as primary sources for study. These items are provided to familiarize you with ADAT examination item formats. These items may not be used for commercial purposes.

The ADA communicates and emphasizes the following cautions to candidates and others. All practice items are the copyrighted property of the American Dental Association. These practice items are intended for the use of educators and students within the educational environment or for individual study and may not be reproduced in any format, whether paper or electronic, without expressed written permission of the ADA. The ADA will consider and may grant, on a case-by-case basis, specific requests by dental education programs for reproduction and use of these materials within the educational environment in either print or electronic format. Dental education programs interested in reproducing practice test questions should email adat@ada.org. The request should include an explanation of the intended use and an estimate of the number copies that will be made.

Item #1

Patient
Male, 45 years old
Chief Complaint
"My teeth wiggle and feel loose."
Background and/or Patient History
Recently lost his job and has been drinking heavily for the last three months Currently homeless
Current Findings
Loose teeth Prolonged gingival bleeding

Based on the patient's history and prolonged gingival bleeding, the function of which organ is compromised?

- A: Kidney
- B: Liver
- C: Pancreas
- D: Spleen

Item #2

Surgical procedures involving the parotid gland pose the greatest risk of damage to the

- A: facial artery.
- B: facial vein.
- C: internal carotid artery.
- D: retromandibular vein.

Item #3

Which stratum layer of the epidermis contains stem cells undergoing mitosis?

A: Basale

B: Corneum

C: Granulosum

D: Lucidum

E: Spinosum

Item #4

What inflammatory cell would predominate in chronic sialadenitis if a biopsy is performed?

A: Eosinophils

B: Lymphocytes

C: Macrophages

D: Neutrophils

Item #5

Which type of bone cells secrete collagenase?

A: Osteoblasts

B: Osteochondral progenitor cells

C: Osteoclasts

D: Osteocytes

Item #6

Which chemical or compound is most toxic to hepatocytes?

A: Chloroform

B: Chromium

C: Mercury

D: Salicylic acid

Item #7

Which form of glucose is responsible for the glycation of proteins?

A: Alpha-anomer

B: Beta-anomer

C: Linear unbranched

D: Phosphorylated

Item #8

Circular folds, intestinal villi, and brush border contribute to the digestion and absorption process in the small intestine by

A: maximizing the surface area.

B: neutralizing acids from the stomach.

C: protecting the mucosal barrier from proteolytic enzymes.

D: regulating the flow of bile.

Item #9

Patient
Male, 20 years old
Chief Complaint
"My gums bleed every time I brush my teeth."
Background and/or Patient History
Uncontrolled type 1 diabetes Recent hospitalization after automobile accident
Current Findings
Aggressive periodontitis Elevated HbA1c Radiographic evidence of alveolar bone loss

How might the stress of the automobile accident have impacted glucose control?

- A: Decreased glucose control due to cortisol release
- B: Decreased glucose control due to glucagon release
- C: Increased glucose control due to epinephrine release
- D: Increased glucose control due to norepinephrine release

Item #10

Addison's disease is characterized by

- A. excess adrenal androgen production.
- B. hyperfunction of the adrenal cortex.
- C. hypofunction of the adrenal cortex.
- D. increased glycolysis.

Item #11

The urinalysis of a 3-month-old female with signs of neurological defects reveals abnormally high levels of several tricarboxylic acid (TCA) cycle intermediates such as fumarate, succinate, α -ketoglutarate citrate, and malate. A deficiency in which enzyme is the most likely cause of the patient's condition?

- A: Catalase
- B: Fumarase
- C: Hexokinase
- D: Sucrase

Item #12

Patient
Female, 3 years old
Chief Complaint
"My daughter's teeth are loose and falling out."
Background and/or Patient History
No history of facial injury
Current Findings
Normal root morphology for lost tooth Anterior teeth mobility

What is the most likely diagnosis?

- A: Amelogenesis imperfecta
- B: Dentinogenesis imperfecta
- C: Hypophosphatasia
- D: Tricho-dento-osseous syndrome

Item #13

The offspring of a genotypically normal mother and a father with an X-linked recessive disease will produce

- A: 50% affected sons.
- B: 100% affected sons.
- C: 100% affected daughters.
- D: 100% carrier daughters.

Item #14

During the hemostasis coagulation cascade, exposure of which pericytes membrane protein results in the initiation of the extrinsic pathway?

- A: Factor III
- B: Factor V
- C: Factor VII
- D: Factor X

Item #15

Each of the following molecules can be transported through gap junctions in the cell membrane EXCEPT one. Which is the EXCEPTION?

- A: Calcium
- B: Cyclic adenosine monophosphate
- C: Inositol triphosphate
- D: Protein

Item #16

The analgesic effect of nitrous oxide is the result of activation of the

- A: alveolar gradient.
- B: benzodiazepine binding site.
- C: gamma-aminobutyric acid (GABA) receptors.
- D: opioid receptors.

Item #17

Which type of neuroglia produces myelin in the central nervous system?

- A: Astrocytes
- B: Oligodendrocytes
- C: Satellite cells
- D: Schwann cells

Item #18

Loss of muscle function in the jaw and shoulders is characteristic of

- A: Becker muscular dystrophy.
- B: facioscapulohumeral muscular dystrophy.
- C: mitochondrial mutation-related dystrophy.
- D: myasthenia gravis.

Item #19

The presence of antibodies that act against acetylcholine receptors is characteristic of

- A: mitochondrial mutation-related dystrophy.
- B: myastheniagravis.
- C: myositis ossificans.
- D: myotonia congenita.

Item #20

What is a common complication of large acute myocardial infarcts?

- A: Aortic valve fragmentation
- B: Growth of the aorta
- C: Increased longitudinal growth of the skeleton
- D: Pump or congestive heart failure

Item #21

Each of the following exacerbates polymerization of hemoglobin in a patient with sickle cell anemia EXCEPT one. Which is the EXCEPTION?

- A: Acidosis
- B: High carbon dioxide tension
- C: High oxygen tension
- D: Intense exercise

Item #22

Patient
Female, 27 years old, Caucasian
Chief Complaint
"I have a painful molar, especially with iced tea."
Background and/or Patient History
Asthma Atopic dermatitis
Current Findings
Severe caries Pulpal necrosis

Shortly after receiving local anesthetic, the patient complains of nausea, dyspnea, and tingling around the lips, which are edematous. Each element of the dental environment may provoke these symptoms EXCEPT one. Which is the EXCEPTION?

- A: Bronchodilation
- B: Increase in capillary permeability
- C: Release of immunoglobulin E-mediated histamine
- D: Type I allergic hypersensitivity reaction

Item #23

What microorganism is known for its propensity for maxillary sinus involvement?

- A: Candida albicans
- B: Human papilloma virus (HPV)
- C: Mucormycosis
- D: Paracoccidioidomycosis

Item #24

The component of the outer membrane of gram-negative bacteria that stimulates the host immune response and causes tissue damage is a/an

- A: endotoxin.
- B: exotoxin.
- C: neurotoxin.
- D: superantigen.

Item #25

Which of the following is characteristic of the hydropic degeneration of hepatocytes?

- A: Accumulation of large lipid deposits within the cell
- B: Fluid and metabolite accumulation within the cell
- C: Hyaline droplet accumulation within the cell
- D: Water displacement of the endoplasmic reticulum

Item #26

Histological examination of a biopsy from a cyst taken from a lower lip reveals a cystic cavity filled with mucus and surrounded by a layer of granulation tissue. The most likely cause of this lesion is trauma to the

- A: blood vessels in the lamina propria.
- B: minor salivary glands.
- C: stratified squamous non-keratinized epithelium.
- D: sublingual gland.

Item #27

Which chemical mediator is the most reliable marker of inflammation?

- A: Bradykinin
- B: C-reactive protein
- C: Glucagon
- D: Opsonin

Item #28

What is the underlying mechanism responsible for the development of an indurated area following a tuberculin injection?

- A: Immediate type (type I) reaction
- B: Antibody-mediated (type II) hypersensitivity
- C: Immune complex-mediated (type III) reaction
- D: Cell-mediated (type IV) hypersensitivity

Item #29

Marfan syndrome is caused by a mutation in the gene coding for which protein?

- A: Collagen type 1
- B: Elastin
- C: Fibrillin
- D: Fibronectin

Item #30

Patient
Female, 46 years old
Chief Complaint
"My jaw hurts, and I have difficulty opening my mouth."
Background and/or Patient History
Sensitive teeth and bleeding gums beginning about 5 years ago Arthritis Multiple joint pain Pulmonary arterial hypertension Systemic sclerosis, diagnosed approximately 9 years ago
Unable to work Non-smoker
Current Findings
Heavy plaque accumulation Multiple caries Areas of gingival recession Minimal tooth mobility Limited mouth opening Partially erupted, malpositioned third molars

The patient at highest risk for which syndrome?

- A: Behçet
- B: Gardner
- C: Peutz-Jeghers
- D: Secondary Sjögren

Item #31

What is a common complication of Crohn's disease?

- A: Adenocarcinoma of the small intestine
- B: Columnar metaplasia of the esophagus
- C: Pseudomembranes covering the ulcerated surface
- D: Thickening of the bowel wall due to inflammation

Item #32

Each of the following teeth have a transverse ridge EXCEPT one. Which is the EXCEPTION?

- A: Mandibular first premolar
- B: Maxillary incisor
- C: Maxillary first premolar
- D: Maxillary second premolar

Item #33

Which pairs of teeth have their cingula offset to the distal?

- A: Maxillary central incisors and mandibular central incisors
- B: Maxillary central incisors and mandibular lateral incisors
- C: Maxillary lateral incisors and mandibular central incisors
- D: Maxillary lateral incisors and maxillary central incisors

Item #34

Which is the best anatomical landmark to identify the location of the pulp canal space on tooth 6?

A: Cusp tip

B: Distal concavity

C: Lingual ridge

D: Mesial marginal ridge

Item #35

Patient
Female, 16 years old
Chief Complaint
"I still have a baby tooth, and I see it when I smile."
Background and/or Patient History
Medications: Oral contraceptive
Current Findings
Retained tooth C Excellent home care

The most likely reason for the chief complaint is

A: agenesis of tooth 6.

B: dentigerous cyst.

C: impaction of tooth 6.

D: normal eruption.

Item #36

When calcification occurs within the pulpal space due to trauma or irritation, what pattern does it follow?

- A: Calcification from the apex to the coronal
- B: Calcification from the coronal to the apex
- C: Calcification only near the site of irritation
- D: Calcification of the lateral canals

Item #37

Tooth 19 usually occludes with which teeth in a Class I occlusion?

- A: 12 and 13
- B: 13 and 14
- C: 14 and 15
- D: 15 and 16

Item #38

What is the malocclusion type when the facial cusp of tooth 28 contacts the mesial marginal ridge 4?

- A: I
- B: II
- C: III
- D: IV

Item #39

An x-ray of the maxillary third molars reveals a small, calcified radiopaque mass distal to the third molar. Which is the most likely reason for this mass?

A: Compound odontoma

B: Dens in dente

C: Distodens

D: Mesiodens

Item #40

Patient
Male, 18 years old
Chief Complaint
"My jaw makes a clicking noise when I open it."
Background and/or Patient History
Elbowed in jaw during a basketball game Injury occurred one week ago
Current Findings
Non-painful clicking of right TMJ No history of prior symptoms Occlusion appears stable

The patient reports the clicking is gone when seen at a recall appointment two weeks later. What is the recommended ongoing treatment?

A: Advise gradual return to normal function

B: Fabricate an occlusal splint

C: Prescribe muscle relaxants for 10 days

D: Refer for steroid injections to the joint

Item #41

Patient
Male, 12 years old
Chief Complaint
Mother: "My son was injured during a softball game. He was hit in the face by the ball."
Background and/or Patient History
Facial trauma No loss of consciousness Otherwise healthy
Current Findings
Complicated fracture of tooth 8 with fractured piece retrieved Avulsion of tooth 9, mother has tooth in container with water Patient presents to office within 25 minutes of traumatic incident

What is the priority in management of this patient?

- A: Assess pulp and place interim restoration of tooth 8
- B: Perform pulpotomy, reimplant, and splint tooth 9
- C: Re-attach fractured tooth with composite
- D: Reimplant and splint tooth 9

Item #42

A composite resin material with a lower viscosity would likely also have a

- A: higher hardness.
- B: higher polymerization shrinkage.
- C: higher modulus of elasticity.
- D: lower water sorption.

Item #43

The addition of less than 50 atomic percent of copper to gold in the production of a gold casting alloy will achieve a/an

- A: decrease in the melting temperature.
- B: decrease in the strength.
- C: increase in corrosion resistance.
- D: increase in elongation.

Item #44

Patient
Female, 20 years old
Chief Complaint
"My tooth hurts on and off, and the pain wakes me up at night."
Background and/or Patient History
Periodic pain associated with tooth 8 for the last year Fistula in the buccal maxillary vestibule
Current Findings
Large cervical caries on tooth 8, painful to percussion Large periapical radiolucency associated with tooth 8 revealed by radiograph Biopsy revealed epithelium-lined cavity

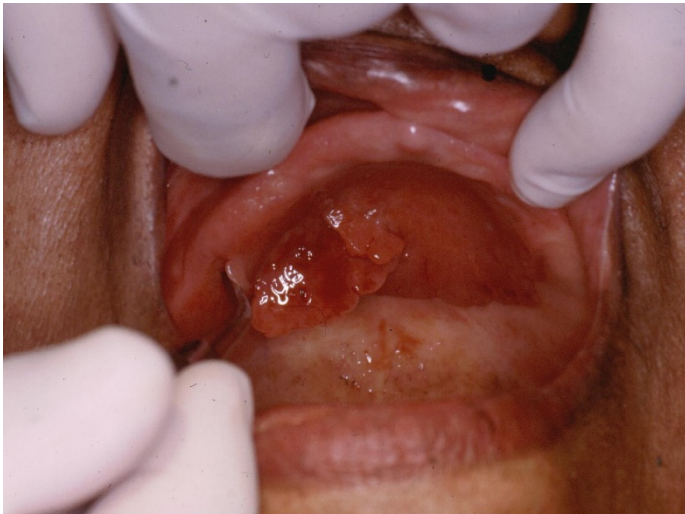What is the most likely diagnosis?

- A: Ameloblastoma
- B: Periapical cyst
- C: Periapical granuloma
- D: Periapical scar

Item #45

Patient
Female, 85 years old
Chief Complaint
"I don't like the way my dentures look."
Background and/or Patient History
Osteoarthritis Right hip replacement 10 years ago Moderate hypertension controlled with a calcium channel blocker Patient reports well-fitting dentures
Current Findings
Lesion as shown in associated image Patient unaware lesion bleeds when manipulated, denies pain Lesion is attached to the palatal tissue through a 10mm pedunculated base

What is the first step in management of this patient?

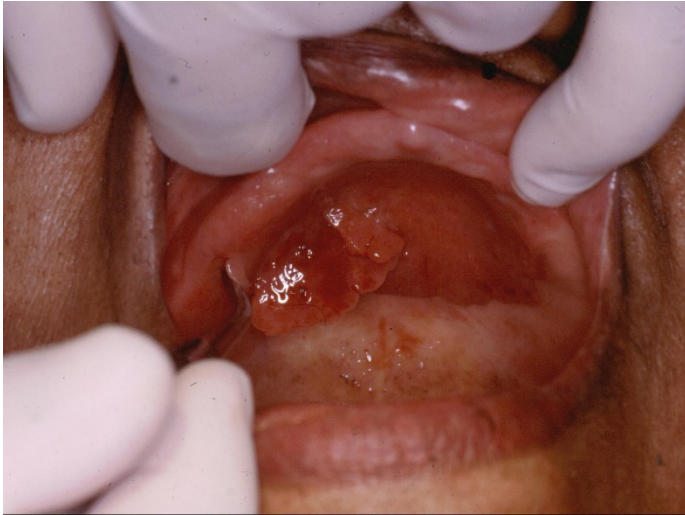

- A: Perform an excisional biopsy
- B: Perform an incisional biopsy
- C: Perform a soft acrylic reline of the existing denture
- D: Request the patient remove the denture for two weeks and re-evaluate

Item #46

Patient
Female, 85 years old
Chief Complaint
"I don't like the way my dentures look."
Background and/or Patient History
Osteoarthritis Right hip replacement 10 years ago Moderate hypertension controlled with a calcium channel blocker Patient reports well-fitting dentures
Current Findings
Lesion as shown in associated image Patient unaware lesion bleeds when manipulated, denies pain Lesion is attached to the palatal tissue through a 10mm pedunculated base

The provisional diagnosis is

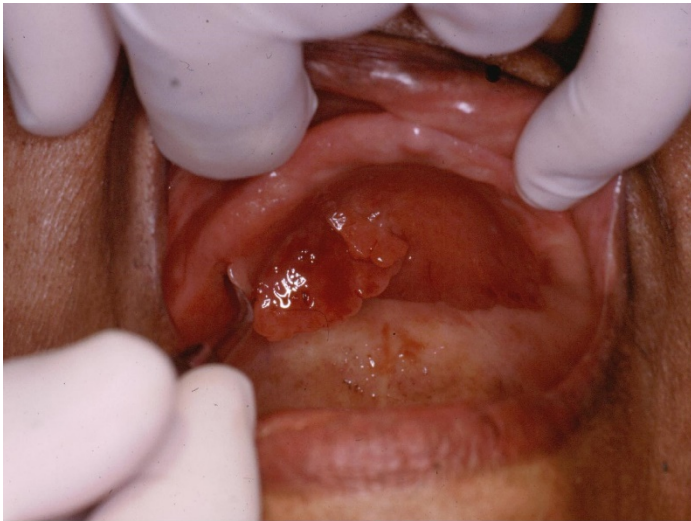

- A: inflammatory hyperplasia.
- B: drug-induced tissue hyperplasia.
- C: squamous cell carcinoma.
- D: verrucous carcinoma.

Item #47

Patient
Female, 85 years old
Chief Complaint
"I don't like the way my dentures look."
Background and/or Patient History
Osteoarthritis Right hip replacement 10 years ago Moderate hypertension controlled with a calcium channel blocker Patient reports well-fitting dentures
Current Findings
Lesion as shown in associated image Patient unaware lesion bleeds when manipulated, denies pain Lesion is attached to the palatal tissue through a 10mm pedunculated base

Following the definitive removal of the lesion, the dentist



- A: fabricates a new denture.
- B: prescribes a once-monthly antifungal rinse and fabricates a new denture.
- C: prescribes topical steroids to prevent recurrence and fabricates a new denture.
- D: requests the patient's primary health care provider change the antihypertensive medication, and fabricates a new denture.

Item #48

Patient
Female, 25 years old, Caucasian
Chief Complaint
"I have a sore in my mouth."
Background and/or Patient History
Current Findings
Single, well-documented, circular, 4mm, brown, flat, non-palpable lesion on soft palate

What is the most likely diagnosis?

- A: Hemangioma
- B: Melanoma
- C: Oral melanotic macule
- D: Smoker's melanosis

Item #49

Patient
Female, 12 years old
Chief Complaint
"I'm not sure why my mom brought me here."
Background and/or Patient History
Current Findings
Cranial base length two standard deviations shorter than normal Remaining cephalometric measurements within normal limits

Which Angle's classification is most likely?

- A: Class I
- B: Class II Division I
- C: Class II Division II
- D: Class III

Item #50

Symptomatic erosive lichen planus is best treated with

A: acyclovir (Zovirax[®]) ointment.

B: antibiotics.

C: surgical excision.

D: topical steroids.

Item #51

Patient
Female, 14 years old
Chief Complaint
"I have had pain and swelling one week after having a molar pulled."
Background and/or Patient History
Juvenile rheumatoid arthritis
Current medications:
Methotrexate (Rheumatrex [®])
Adalimumab (Humira [®])
No known allergies
Current Findings
Indurated swelling of submandibular space on the right side
Oral temp of 100.7° F
BP: 125/83
Heart Rate: 92 BPM
Difficulty swallowing

The dentist has prescribed hydrocodone/acetaminophen for analgesia, but the patient reports inadequate relief. Which explanation is most likely?

A: Drug interaction with adalimumab rendering hydrocodone/acetaminophen ineffective

B: Generic polymorphism in drug-metabolizing enzymes

C: Increased renal clearance of hydrocodone/acetaminophen

D: Poor oral bioavailability of hydrocodone

Item #52

Patient
Male, 65 years old
Chief Complaint
"I don't feel like my dentures are fitting right."
Background and/or Patient History
Has been wearing dentures for the past year
Current Findings
Recently began taking a daily tricyclic antidepressant medication

What condition may be contributing to the chief complaint?

- A: Muscle trismus
- B: Retracted tongue
- C: Stomatitis
- D: Xerostomia

Item #53

Patient
Female, 28 years old
Chief Complaint
"I need an implant to fix my missing upper front tooth."
Background and/or Patient History
Involved in a car accident six months ago Tooth 8 fractured and was extracted
Current Findings
Complete clinical healing of socket with minimal bone loss

The ideal distance between the superior surface of the implant and the inferior portion of the gingival emergence position of the planned restoration is

- A: 0.5 to 1.0 mm.
- B: 1.5 to 2.0 mm.
- C: 2.5 to 3.0 mm.
- D: 4.0 to 5.0 mm.

Item #54

Which statement is correct regarding the establishment of the occlusal plane in the fabrication of a complete denture?

- A: The closest speaking space ("S" sound) is used to verify the occlusal plane.
- B: The Curve of Spee follows the frontal plane.
- C: The mandibular first molar is usually at a level two-thirds of the way up the retromolar pad.
- D: The occlusal plane is parallel to the Frankfort horizontal plane.

Item #55

For a study to be considered a randomized controlled trial, participants must be

- A: blinded to their experimental condition.
- B: randomly assigned to experimental conditions.
- C: randomly drawn from multiple populations.
- D: randomly selected from the population of interest.

Item #56

The goal of a meta-analysis is to

- A: replicate the results of a single study.
- B: replicate the results of multiple studies.
- C: summarize the results of a single study.
- D: summarize the results of multiple studies.

Item #57

For a study to be considered a crossover trial,

- A: a cohort of participants must be followed from childhood to adulthood.
- B: each participant must experience multiple experimental conditions.
- C: participants must be blinded to their experimental condition.
- D: the study results must generalize to multiple populations.

Item #58

Power analyses are used to

A: compare the relative importance of two risk factors.

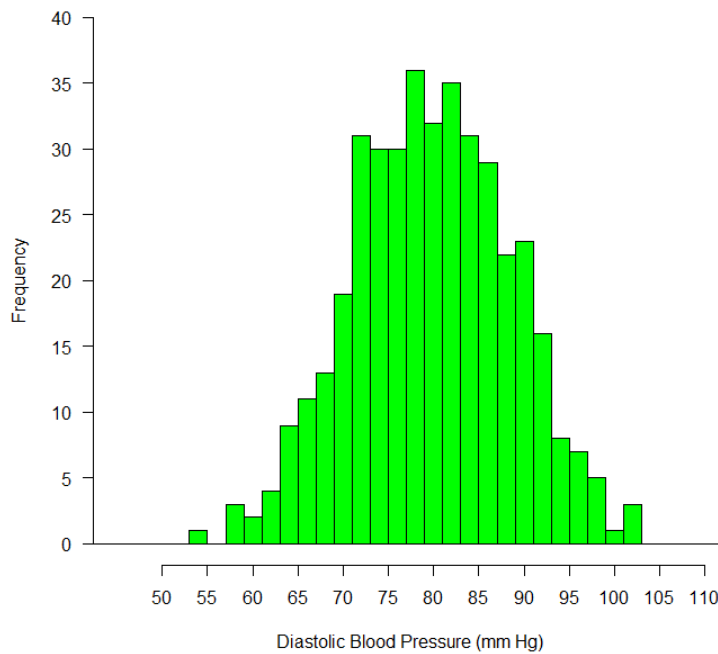
B: determine the number of participants needed for a study.

C: determine the strength of the treatment effect.

D: establish a causal relationship between a treatment and an outcome.

Item #59

The graph below shows the distribution of diastolic blood pressure in a sample of 400 dental patients.



The first quartile of the distribution is closest to which diastolic blood pressure value?

A: 63

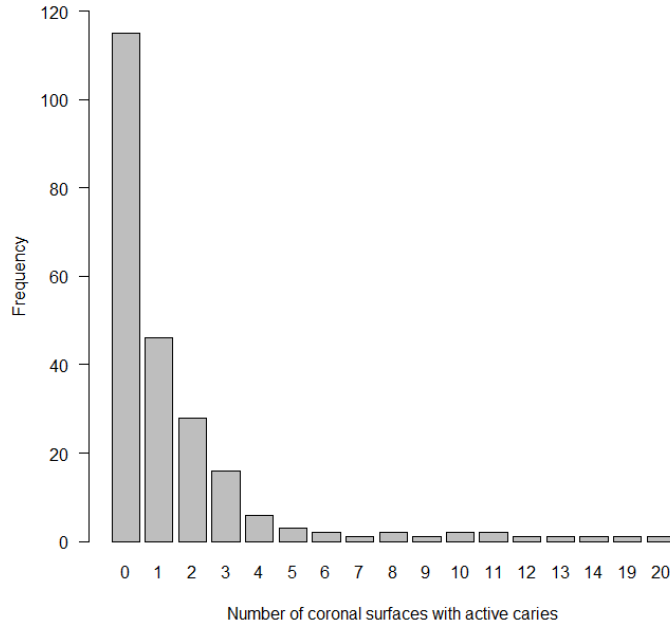
B: 73

C: 83

D: 93

Item #60

The graph below shows the distribution of the number of coronal surfaces with active caries in a sample of 300 seniors.



Based on the graph, which statistic will have the highest value?

- A: 10th percentile
- B: Mean
- C: Median
- D: Mode

Item #61

A new diagnostic saliva test for periodontal disease was evaluated using a sample of 105 patients whose true condition was known. The results are presented in the table.

		True Disease Status	
		Positive	Negative
Test Result	Positive	4	1
	Negative	1	99

What is the sensitivity of this diagnostic test?

A: 4/4

B: 4/5

C: 1/99

D: 99/100

Item #62

A study examined the relationship between smoking and dental implant failure in a sample of 300 patients. Data from the study are presented in the table.

	Dental Implant Failure	
	Yes	No
Smoker	10	90
Non-smoker	10	190

Based on the table, what is the relative risk (RR) of dental implant failure associated with smoking?

A: 1.0

B: 1.5

C: 2.0

D: 2.5

Item #63

The results of a hypothesis test indicate that the p-value is greater than the alpha level of 0.05. From this, the reader can conclude that the result was

- A: clinically significant.
- B: statistically biased.
- C: statistically significant.
- D: not statistically significant.

Item #64

A study examined the relationship between smoking and dental implant failure in a sample of 300 patients. Results were as follows:

	Dental Implant Failure	
	Yes	No
Smoker	10	90
Non-smoker	10	190

These results suggest that

- A: smokers and non-smokers are equally likely to get dental implants.
- B: smokers and non-smokers experience implant failure at the same rate.
- C: the majority of smokers in the sample experienced implant failure.
- D: there is a relationship between smoking and implant failure.

Item #65

A study examined the association between diabetes and periodontal disease. The results indicated that the risk of periodontal disease was 10% for those with diabetes, and 5% for those without diabetes. What is the *absolute risk increase* associated with diabetes?

A: 0.5%

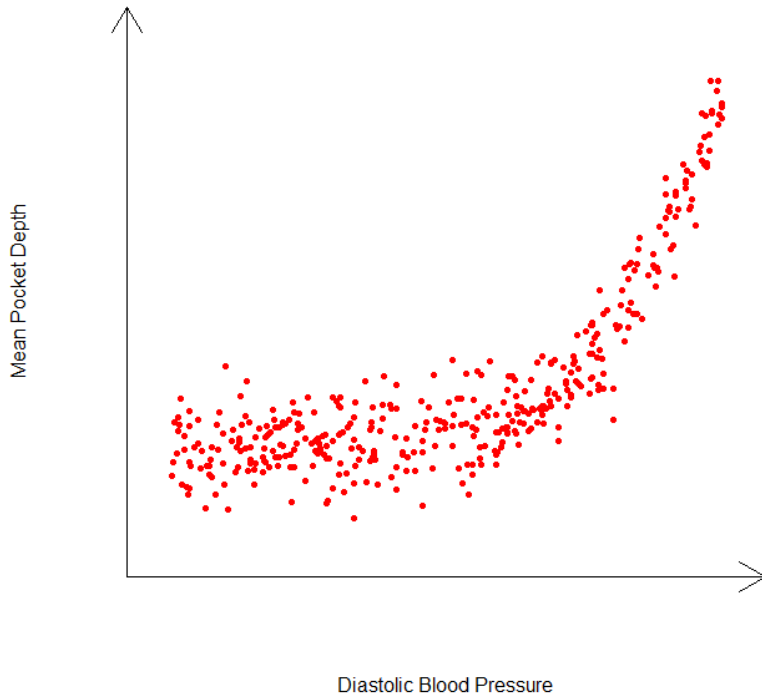
B: 2%

C: 5%

D: 10%

Item #66

The plot depicts the relationship between diastolic blood pressure (mm Hg) and mean pocket depth (mm) in a sample of 400 patients.



Based on the plot, the relationship between diastolic blood pressure and mean pocked depth is

- A: linear and gets stronger as diastolic blood pressure increases.
- B: linear and gets weaker as diastolic blood pressure increases.
- C: nonlinear and gets stronger as diastolic blood pressure increases.
- D: nonlinear and gets weaker as diastolic blood pressure increases.

Item #67

Statistical hypothesis testing requires each of the following EXCEPT one. Which is the EXCEPTION?

- A: Calculation of a p-value
- B: Establishment of a causal relationship
- C: Establishment of a null hypothesis
- D: Establishment of an alpha level

Item #68

A confidence interval for a treatment effect represents a/an

- A: interval estimate of the effect in the population.
- B: interval estimate of the power of the analysis.
- C: point estimate of the effect in the population.
- D: point estimate of the power of the analysis.

Item #69

Confidence intervals require each of the following EXCEPT one. Which is the EXCEPTION?

- A: Calculation of a margin of error
- B: Calculation of a point estimate
- C: Determination of a p-value
- D: Establishment of a confidence level

Item #70

Four studies examined the association between diabetes and dental implant failure. The table below summarizes the results of a meta-analytic review involving these studies.

Study	Risk Ratio [95% confidence interval]
1	0.10 [0.01, 1.64]
2	0.57 [0.23, 1.39]
3	1.15 [0.74, 1.79]
4	3.35 [0.70, 15.96]
Overall Estimate	0.90 [0.62, 1.32]

Assuming an alpha level of 0.05, which statement is true?

- A: All four studies found a statistically significant association; the overall association is not statistically significant.
- B: All four studies found a statistically significant association; the overall association is statistically significant.
- C: None of the four studies found a statistically significant association; the overall association is not statistically significant.
- D: None of the four studies found a statistically significant association; the overall association is statistically significant.

Item #71

A child patient presents with linear wrist burns and bruises on both arms. The child's parent says the child is clumsy, falls a lot, and bumps into furniture. The dentist suspects abuse. What ethical principle is involved in the dentist's decision to contact child protective services?

- A: Autonomy
- B: Beneficence
- C: Justice
- D: Nonmaleficence

Item #72

The dentist extracts the tooth of a patient with hemophilia A without obtaining a medical consultation. The extraction site immediately starts to bleed profusely and the bleeding cannot be stopped. What ethical principle has been violated?

- A: Autonomy
- B: Beneficence
- C: Justice
- D: Nonmaleficence

Item #73

A patient wants a fractured tooth extracted. The dentist tells the patient that the tooth is restorable. What two ethical principles are in conflict?

- A: Beneficence and autonomy
- B: Beneficence and justice
- C: Justice and veracity
- D: Maleficence and veracity

Item #74

In managing a child patient's dental anxiety, what best exemplifies the behavioral strategy known as modeling?

- A: Allow the patient to observe another patient who is coping successfully with the procedure
- B: Ask the patient to pretend to be someone else who can cope well with the procedure
- C: Demonstrate to the patient what procedures will be carried out on a model
- D: Have the patient rehearse appropriate behavior

Item #75

Which statement is true regarding programs that intend to improve patient success with preventive oral health behaviors, such as flossing?

- A: They initially succeed, but the success rate usually declines over time.
- B: They initially succeed, but will fail if patients are not properly educated.
- C: They usually fail because patients are resistant to change.
- D: They usually succeed if patients believe in prevention.

Item #76

Patient
Male, 57 years old
Chief Complaint
"I woke up with a very swollen face and a bad toothache."
Background and/or Patient History
Penicillin allergy Congestive heart failure - well controlled
Medications
Digoxin (Lanoxin®)
Current Findings
Diffuse, non-focal facial swelling of lower right quadrant Vitality testing shows tooth 30 to be non-vital Periapical radiograph shows a radiolucent area apical to the mesial roots of tooth 30 Tooth 30 is restorable and periodontally healthy

If initiation of endodontic therapy on tooth 30 provides no drainage, the dentist should prescribe an antibiotic regimen of

- A: azithromycin (Zithromax®).
- B: clindamycin (Cleocin®).
- C: erythromycin (EryPed®).
- D: tetracycline.

Item #77

Metronidazole (Flagyl®) should be avoided in a well-managed patient with bipolar disorder who is taking lithium because

- A: an enhanced hypoglycemic reaction can occur.
- B: excess trivalent cationic chelation can occur.
- C: lithium toxicity and kidney damage can occur.
- D: peptic ulcer and gastro-intestinal inflammation can occur.

Item #78

Patient
Female, 48 years old
Chief Complaint
"I have a broken tooth that hurts."
Background and/or Patient History
History of atrial fibrillation
Current Medications:
Clopidogrel (Plavix®)
Current Findings
Carious non-restorable tooth 4, requires simple extraction Patient reports pain is 8 on a scale of 1-10 Tooth is grade 2 mobile

The patient presents with a letter from her physician saying that she should discontinue use of clopidogrel for two days prior to extraction, but she has not stopped taking this medication. How should the dentist proceed with treatment?

- A: Call the patient's physician to discuss the consultation and current guidelines, and then proceed with the extraction.
- B: Have the patient discontinue clopidogrel and instruct her to return in two days for the extraction.
- C: Perform the extraction that day because current guidelines do not suggest discontinuing clopidogrel prior to extraction.
- D: Suggest the patient see another physician for a second opinion.

Item #79

Each of the following is a concern related to treatment of a patient with hypothyroidism EXCEPT one. Which is the EXCEPTION?

- A: Risk of bleeding
- B: Risk of thyroid storm
- C: Susceptibility to cardiovascular disease
- D: Susceptibility to infection

Item #80

What index should be used for children only?

- A: CPITN
- B: df
- C: OHI-S
- D: PI

Item #81

What precautions should the dentist take prior to extracting a tooth from a patient who is HIV-positive and has hepatitis C?

- A: Double glove and double mask
- B: Implement special isolation precautions
- C: Refer patient to an oral surgeon
- D: Treat patient following universal precautions

Item #82

Standard or universal precautions apply to infection control measures in the treatment of

- A: active rhinitis in a young patient.
- B: all patients in the dental office.
- C: HIV-positive patients with a normal CD4 count.
- D: patients with a history of intravenous drug abuse.

Item #83

What should the dentist do first if skin is exposed to a hazardous material?

- A: Blot the area carefully with clean gauze
- B: Flush the area with cold water for five minutes
- C: Flush the area with hydrogen peroxide for five minutes
- D: Remove clothing and jewelry from the affected area

Item #84

As the capacity of a hazardous waste container approaches the fill line, it should be

- A: emptied immediately, sterilized, and reused.
- B: immediately exchanged, properly labeled, dated, and replaced.
- C: monitored twice daily to assess when sterilization is needed.
- D: monitored until full, properly labeled, dated, and replaced.

Item #85

Patient
Female, 43 years old
Chief Complaint
"I'm here for a check-up."
Background and/or Patient History
Smoker: 5 cigarettes per day for 15 years
Current Findings
Clinical exam reveals negative oral cancer screening, generalized bone loss and probing depths to 6 mm that require scaling and root planing.

The patient refuses scaling and root planing because her insurance will not cover it. She says, "I'm not interested in that gum work, and it's too expensive." She agrees to return in six months for an examination and prophylaxis with the hygienist. How should the dentist proceed with treatment?

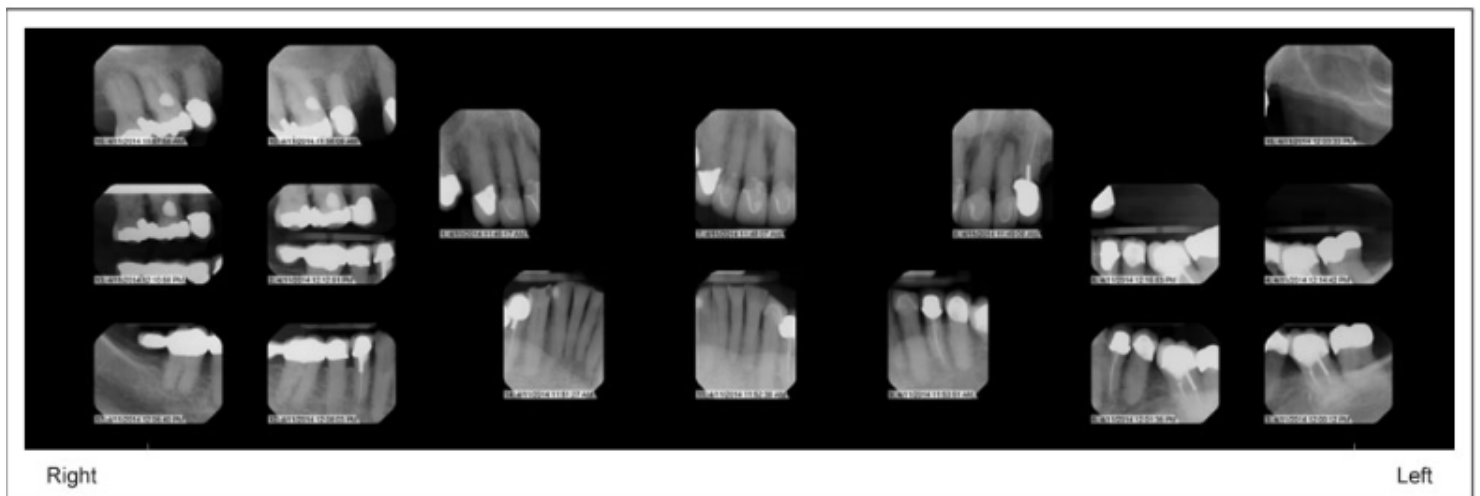
- A: Continue to see the patient, provide three-month examinations and prophylaxes, but do not probe at every visit.
- B: Continue to see the patient, provide six-month examinations and prophylaxes, and continue to probe at every visit.
- C: Refer the patient to a more cost-effective treatment facility.
- D: Refuse to treat the patient because she would be wasting her money on inadequate treatment.

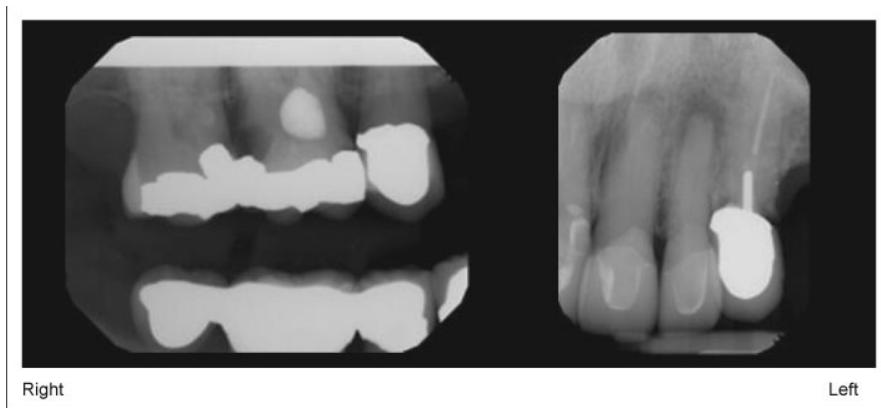
CASE 1

Items 86-91

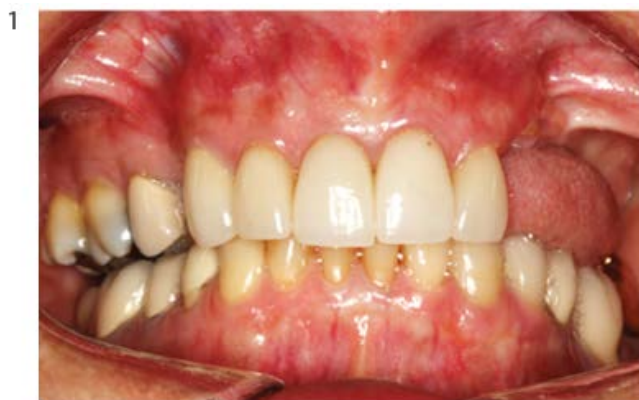Patient
Female, 69 years old
Chief Complaint
"My upper left eye tooth crown keeps falling out. I don't like wearing my upper partial denture."
Background and/or Patient History
High cholesterol Left hip pain from arthritis
<u>Current medications:</u> Pravastatin (Pravachol [®]) 40mg once daily Naproxen (Naprosyn [®]) 500mg twice daily as needed for pain
Last dental appointment was one year ago Fixed restorations were done in United States Maxillary removable partial denture was fabricated in Guatemala 5 years ago
No known drug allergies
Current Findings
BP: 170/81 Pulse: 75 BPM

Radiographs



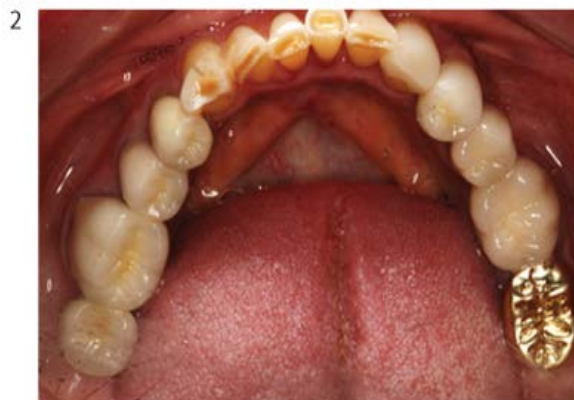

Photographs



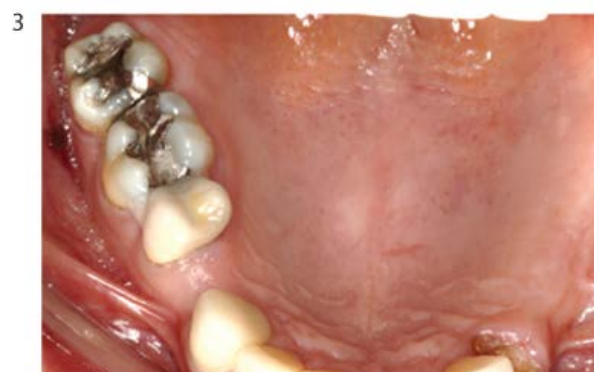Right Side

Left Side



Right Side

Left Side



Right Side

Left Side

Item #86

Tooth 10 is asymptomatic and does not respond to pulp testing. What are the pulpal and periapical diagnoses?

- A: Asymptomatic irreversible pulpitis with chronic apical periodontitis
- B: Irreversible pulpitis with apical abscess
- C: Necrotic pulp with apical abscess
- D: Necrotic pulp with chronic apical periodontitis

Item #87

The carious lesion on tooth 3 approximates the pulp. The tooth responds normally to pulpal testing. What is the pulpal diagnosis?

- A: Asymptomatic irreversible pulpitis
- B: Dentin hypersensitivity
- C: Symptomatic irreversible pulpitis
- D: Symptomatic reversible pulpitis

Item #88

The patient desires a tooth-colored restoration for tooth 3. What is the best method to restore this tooth?

- A: Closed sandwich technique with composite on the gingival floor
- B: Closed sandwich technique with glass ionomer on the gingival floor
- C: Open sandwich technique with composite on the gingival floor
- D: Open sandwich technique with glass ionomer on the gingival floor

Item #89

Clinical examination reveals mandibular incisal dentinal cupping. What is the likely cause of this finding?

- A: Abfraction
- B: Dietary acidic erosion
- C: Enamel hypoplasia
- D: Gastroesophageal reflux

Item #90

During examination, the patient complains of muscle pain, tenderness, and weakness. What is the most appropriate response?

- A: Explain to the patient that she may be allergic to naproxen.
- B: Increase the dose of naproxen.
- C: Refer the patient to her primary care physician for suspected myopathy.
- D: Switch the patient's pain medication to ibuprofen.

Item #91

After extraction of tooth 11, the Kennedy classification is

- A: Class I modification I.
- B: Class II.
- C: Class II modification I.
- D: Class III modification I.

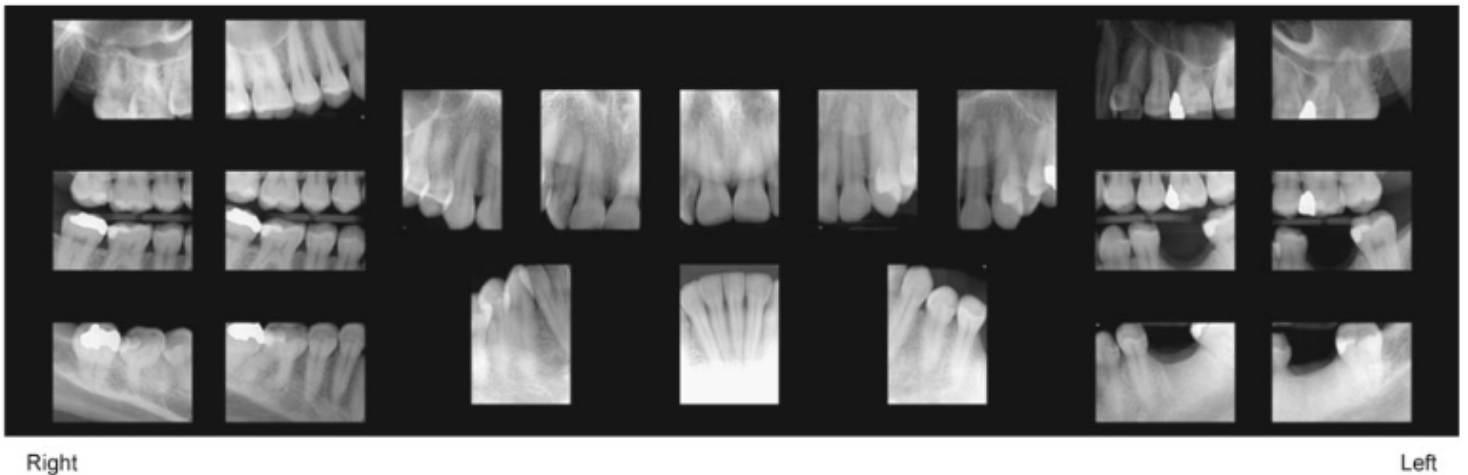
End Case 1

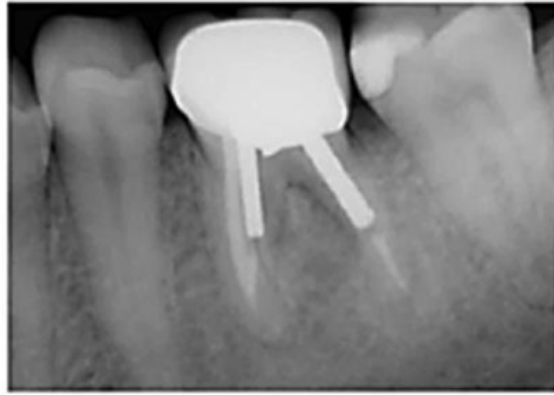CASE 2

Items 92-101

Patient
Male, 33 years old
Chief Complaint
"I want an implant to replace the lower left molar that was extracted last year."
Background and/or Patient History
No significant findings in medical history Lost tooth 19 due to vertical fracture on the distal root following endodontic procedure one year ago No known drug allergies Very physically active Works for a tech company Lives with wife and infant daughter
Current Findings
BP: 145/60 Pulse: 75 BPM Painful response to palpation of gingival tissue in area of tooth 19

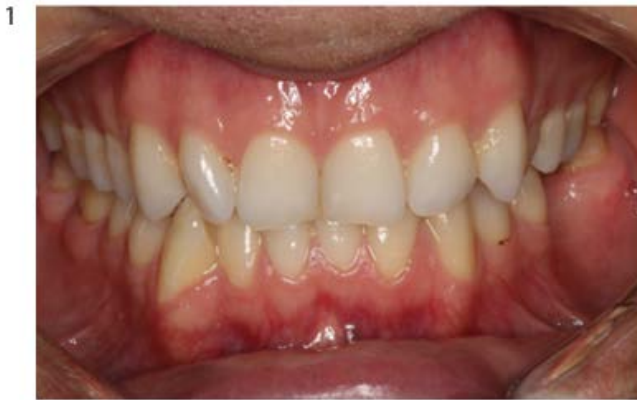Radiographs





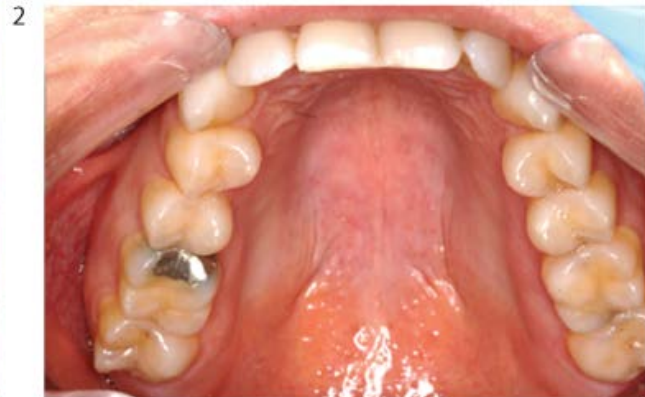PA

Photographs



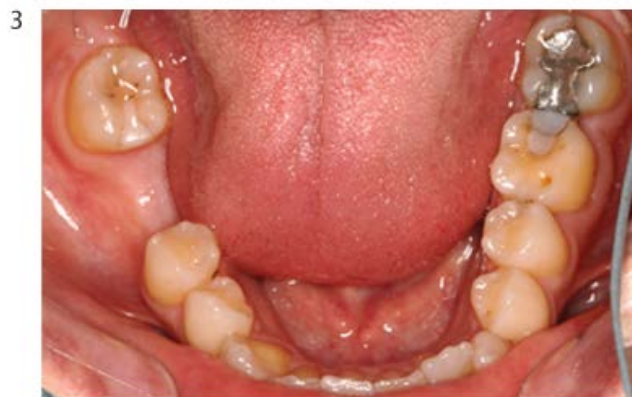Right Side

Left Side



Right Side

Left Side



Right Side

Left Side

Item #92

The patient reports an intense, unilateral, "electric" pain in his lower lip when shaving. The most likely diagnosis is

A: glossopharyngeal neuralgia.

B: migrainous neuralgia.

C: myofacial pain.

D: trigeminal neuralgia.

Item #93

What is the minimum distance required between the apex of the implant and the inferior alveolar canal when placing an implant at site 19?

A: 1 mm

B: 2 mm

C: 4 mm

D: 6 mm

Item #94

The patient was referred to a pain specialist. What medication was likely to have been prescribed for the patient's pain?

A: Carbamazepine (Tegretol[®])

B: Diazepam (Valium[®])

C: Indomethacin (Indocin[®])

D: Oxycodone (Oxycontin[®])

Item #95

Each of the following is a possible differential diagnosis for the radiolucent lesion apical to vital tooth 30 EXCEPT one. Which is the EXCEPTION?

- A: Benign bone radiolucency
- B: Breast cancer metastasis
- C: Periapical abscess
- D: Traumatic bone cyst

Item #96

What is the Angle's classification of malocclusion for this patient?

- A: Class I malocclusion
- B: Class II division 1 malocclusion
- C: Class II division 2 malocclusion
- D: Class III malocclusion

Item #97

What time-frame would be expected for the majority of resorption to have occurred following an uncomplicated dental extraction in the absence of ridge preservation therapy?

- A: 1 month
- B: 3 months
- C: 6 months
- D: 12 months

Item #98

Following the extraction of tooth 19, there is loss of alveolar bone. Which is true regarding the expected pattern of bone resorption?

- A: Equal buccally and lingually
- B: More buccally than lingually
- C: More lingually than buccally

Item #99

What is the best approach to provide adequate keratinized tissue for an implant restoration of site 19?

- A: Bone graft to augment the ridge at site 19 before implant placement
- B: Connective tissue graft at site 19 during implant placement
- C: Extensive free gingival graft from tooth 18 to tooth 20 before implant placement
- D: Lingualized crestal incision during healing abutment placement surgery

Item #100

After clinical examination, what is the correct sequence of events to plan the implant surgery?

- A: Panoramic x-ray, cone beam computerized tomography, scaling and root planing
- B: Scaling and root planing, cone beam computerized tomography, working cast
- C: Working cast, cone beam computerized tomography, panoramic x-ray
- D: Working cast, cone beam computerized tomography, surgical guide

Item #101

Which of the following statements is correct concerning single implant restoration for the mandibular posterior region?

A: A three-unit fixed dental prosthesis has a better long-term prognosis than an implant crown.

B: Cement-retained restoration is indicated for limited inter-arch distance.

C: The minimal mesio-distal distance is 8 mm for a regular-diameter 4 mm implant.

D: There is no benefit to platform switching.

End Case 2

Item #	Key
1	B
2	D
3	A
4	B
5	B
6	A
7	C
8	A
9	A
10	C
11	B
12	C
13	D
14	A
15	D
16	D
17	B
18	B
19	B
20	D
21	C
22	A
23	C
24	A
25	D
26	B
27	B
28	D
29	C
30	D
31	D
32	B
33	B
34	A
35	C
36	B
37	B
38	B
39	C
40	A
41	D
42	B
43	A
44	B
45	A
46	A
47	A
48	C
49	D
50	D
51	B
52	D

Item #	Key
53	C
54	C
55	B
56	D
57	B
58	B
59	B
60	B
61	B
62	C
63	D
64	D
65	C
66	C
67	B
68	A
69	C
70	C
71	B
72	D
73	A
74	A
75	A
76	B
77	C
78	A
79	B
80	B
81	D
82	B
83	D
84	B
85	C
86	D
87	A
88	D
89	B
90	C
91	C
92	D
93	B
94	A
95	C
96	C
97	B
98	B
99	D
100	D
101	C