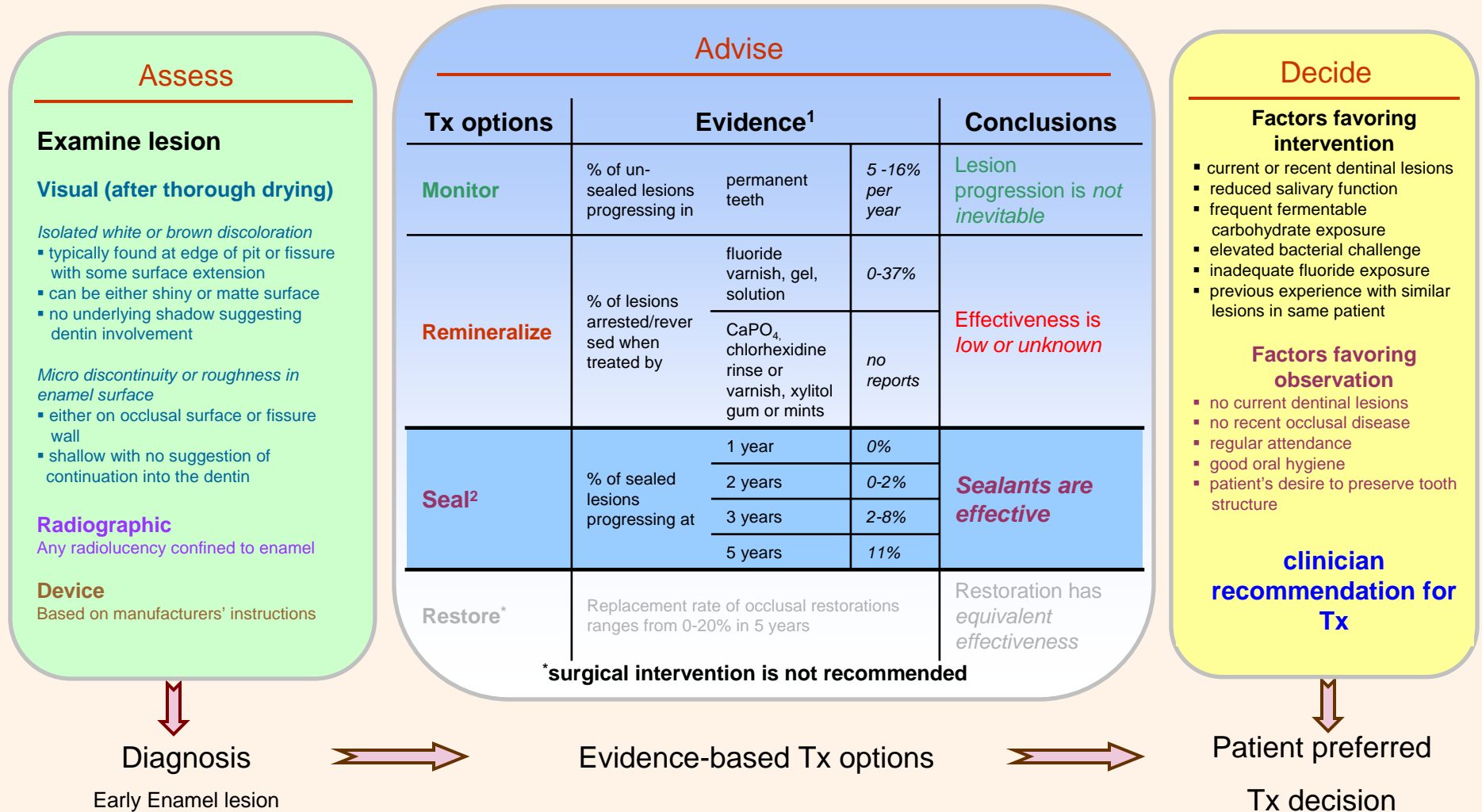


Management of Occlusal Early Enamel Lesions : Current Evidence for Decision Making

Bader J, Shugars D. The evidence supporting alternative management strategies for occlusal caries and suspected occlusal dentinal caries. J Evid Base Dent Pract 2006; 6:91- 100.

Definition : Initial demineralization of occlusal enamel



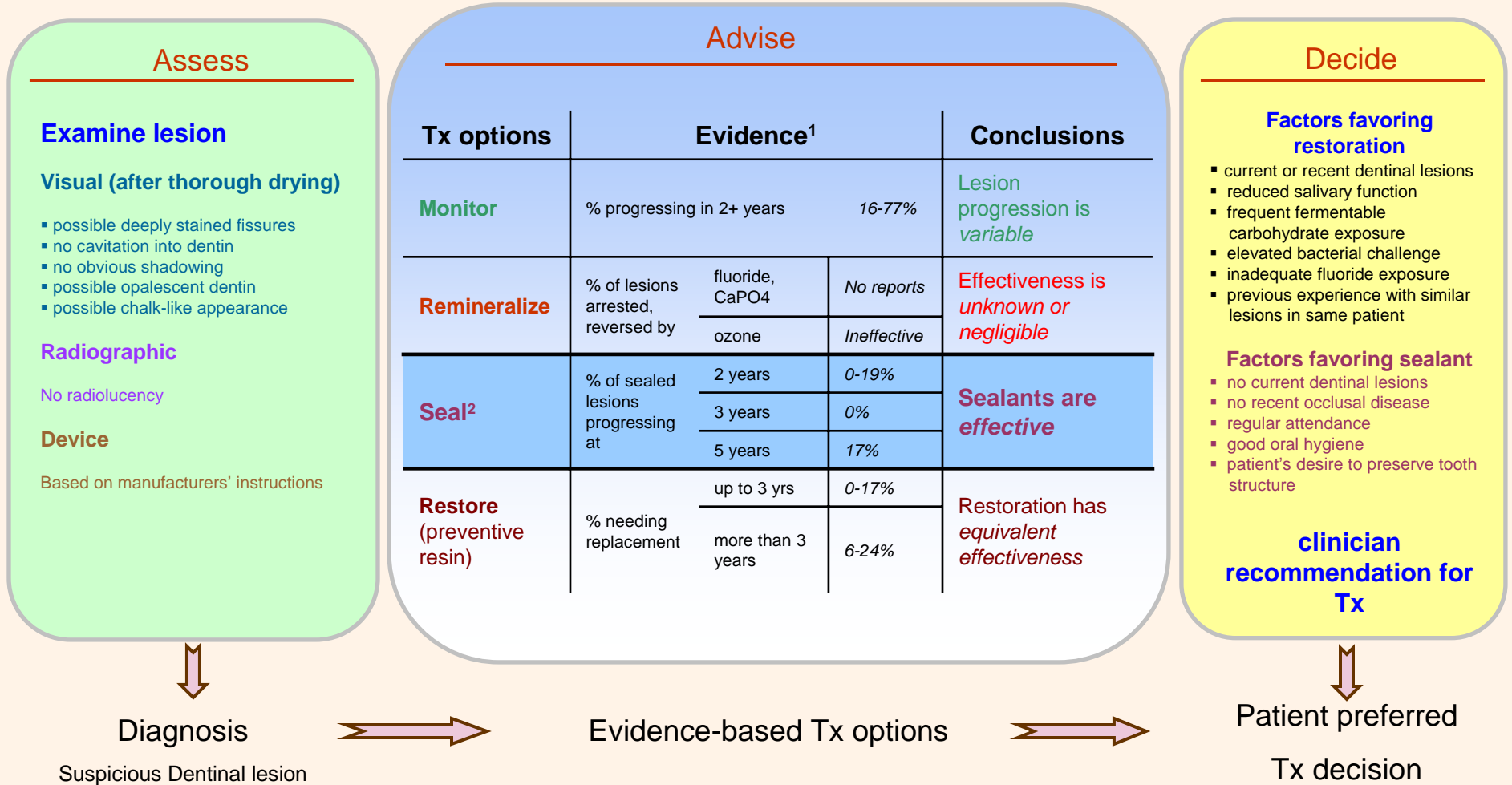
¹Evidence presented here is based on literature searched until 12/31/07.

²Light or auto-polymerized resin-based sealant

Management of Suspicious Dentinal Lesions : Current Evidence for Decision Making

Bader J, Shugars D. The evidence supporting alternative management strategies for occlusal caries and suspected occlusal dentinal caries. J Evid Base Dent Pract 2006; 6:91- 100.

Definition : Occlusal pits or fissures where there is no firm evidence of caries into the dentin, but where subtle color changes or tactile responses cause the clinician to be uncertain.



¹Evidence presented here is based on literature searched until 12/31/07.

²Light or auto-polymerized resin-based sealant